

Case Report

Prenatal Diagnosis of Hydrometrocolpos in a Down Syndrome Fetus

Erik Dosedla, MD,¹ Marian Kacerovsky, MD,² Pavel Calda, MD, PhD³

¹ III. Department of Gynecology and Obstetrics, Slovak Medical University, 1st Private Hospital Košice-Šaca Inc., Košice-Šaca, Slovak Republic

² Department of Obstetrics and Gynaecology, Charles University in Prague, Faculty of Medicine Hradec Kralove, University Hospital Hradec Kralove, Czech Republic

³ Charles University, Prague, First Faculty of Medicine and General Teaching Hospital, Department of Gynecology and Obstetrics, Prague, Czech Republic

Received 21 January 2010; accepted 22 October 2010

ABSTRACT: We report the prenatal sonographic diagnosis of hydrometrocolpos caused by an imperforate hymen in a Down syndrome fetus, with spontaneous evacuation on the third day of life. In this case, sonographic evaluation in the 37th week revealed a large retrovesical, sharply marginated, heterogeneous, unilocular cystic structure within the fetal abdomen extending to the left side of the umbilicus. © 2011 Wiley Periodicals, Inc. *J Clin Ultrasound* 39:169–171, 2011; Published online in Wiley Online Library (wileyonlinelibrary.com) DOI: 10.1002/jcu.20785

Keywords: hydrometrocolpos; Down syndrome; ultrasound; obstetrics

INTRODUCTION

Hydrometrocolpos is defined as distension of the vagina and uterus, either with mucous content generated by uterine and cervical glands, mediated by maternal estrogen production (secretory hydrometrocolpos or mucometrocolpos), or by accumulation of urine in the presence of a vaginal obstruction (urinary hydrometrocolpos).¹ Hydrometrocolpos is a rare congenital abnormality, with an incidence of 1:16,000 neonates.^{2,3} It is most commonly discovered in the third trimester of pregnancy^{3–5} and makes up 15% of abdominal masses found in female fetuses. Generally, reproductive outcomes in chromosomally normal fetuses after drainage of the mucous collection are reported to be good.⁶

CASE REPORT

A 39-year-old woman, gravida 5, para 3, was referred to the department at 37 weeks and 1 day of gestational age because of a pathological cardiotocographic examination and suspicion of fetal growth restriction.

The mother's family history was insignificant. She did not take any drugs during the first 3 months of pregnancy, but she smoked more than 20 cigarettes a day while pregnant. Exposure to other teratogens was negative.

First-trimester aneuploidy screening was not performed, but the ultrasound (US) examination in the 14th week was reported to be normal. Serological tests for toxoplasmosis, rubella, cytomegalovirus, herpes simplex, HIV, hepatitis B surface antigen, and treponema pallidum hemagglutination were negative. The triple test (AFP, hCG, and Estriol) performed at 16 weeks was positive with a risk for trisomy 21 of 1:16. The mother was counseled on the risk of a chromosomal abnormality, but refused an amniocentesis. Morphologic US examination at 20 weeks of pregnancy was recommended, but was refused by the patient. US biometry and morphologic examination of the fetus performed in the 30th week were normal.

Upon the patient's admission at 37 weeks, US examination was performed using an ultrasound system Voluson 730 Expert (GE Medical Systems, Milwaukee, WI) equipped with a convex 4–8 MHz abdominal transducer (RAB 4–8L). It revealed a living female singleton fetus with a composite US age of 33 weeks and 4 days (intrauterine growth restriction of over 4 weeks), anhy-

Correspondence to: P. Calda

© 2011 Wiley Periodicals, Inc.

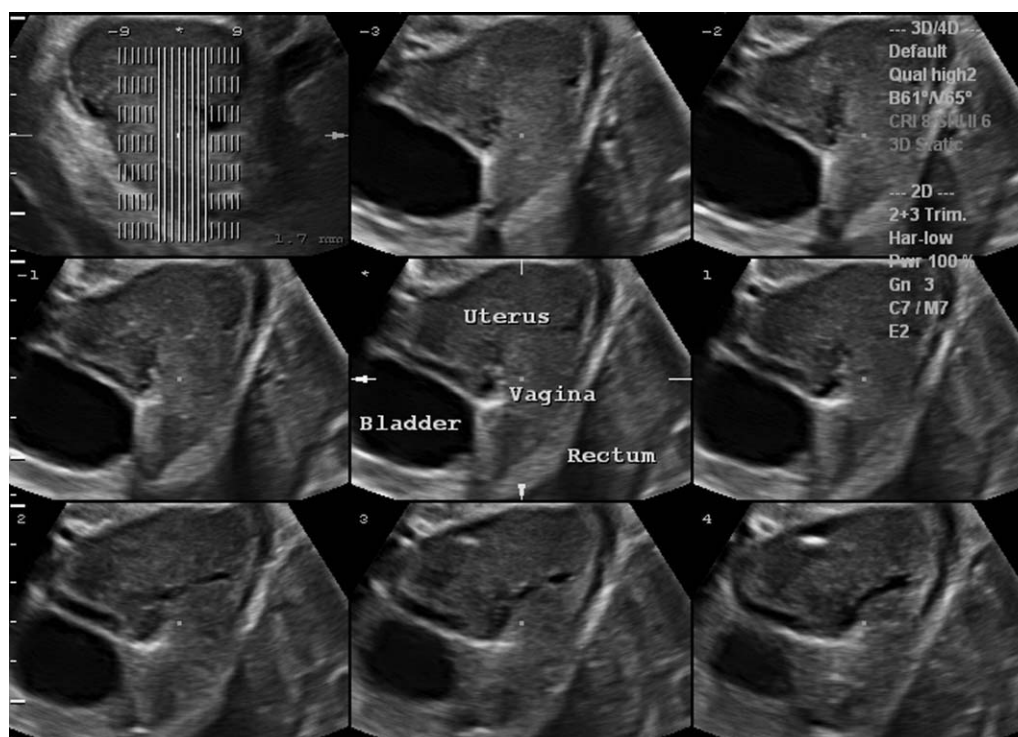


FIGURE 1. Tomographic ultrasound imaging of fetal pelvis shows a set of sagittal slices that demonstrate a large retrovesical hydrometrocolpos.

dramnios, and pathologic (class II) Doppler velocimetry of the umbilical artery. A large retrovesical, sharply margined, heterogeneous, unilocular cystic structure measuring $5.3 \times 4.7 \times 4.3$ cm was seen within the fetal abdomen extending to the umbilical insertion. The anal canal and the rectum were clearly visualized. There was no anomaly of the urinary system. Three-dimensional data sets were also obtained, which were reviewed with tomographic US imaging (Figures 1, 2). No other anomalies were found. The diagnosis of fetal hydrometrocolpos was made based on US findings.

Due to nonreassuring fetal status (biophysical profile of 3/10), a Cesarean section was performed and a female neonate of 2550 g with Apgar score of 6/9/10 was delivered. The neonatal examination revealed typical signs of Down syndrome, a mass in the lower and middle abdomen, and a relatively broad hymen. The diagnosis of hydrometrocolpos was confirmed. Hydrometrocolpos resolved spontaneously on the third day after delivery when the attending physician observed a spontaneous discharge of mucous fluid. The abdominopelvic fluid-filled cystic mass was not seen on a subsequent US examination. The final diagnosis was hydrometrocolpos caused by an imperforate hymen, with spontaneous evacuation on the third day of life. The newborn karyotype revealed trisomy 21 (Down syndrome).

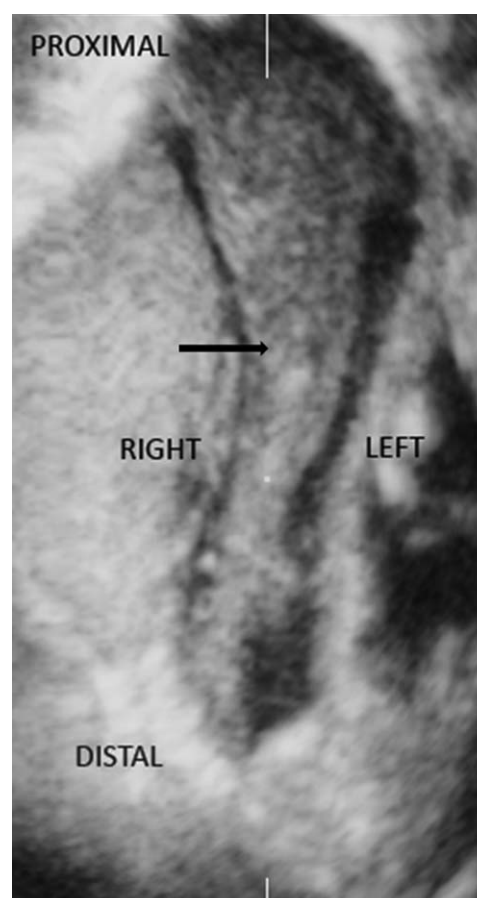


FIGURE 2. Coronal static 3D image combined with volume contrast imaging in C-plane shows the hydrometrocolpos (arrow).

DISCUSSION

In hydrometrocolpos, mucous content accumulates due to imperforate hymen or failure of Müllerian duct fusion.^{4,7} Imperforate hymen is a rare genital anomaly in which a layer of epithelialized connective tissue, which forms the hymen, has no opening and completely obstructs the vaginal introitus.⁸ Prenatal US diagnosis of hydrometrocolpos is rare.⁹ In the present study, the ultrasound appearance of the hydrometrocolpos was nearly solid because of the mucous content of the mass and, therefore, the lesion would be better characterized as *mucometrocolpos*. When hydrometrocolpos is suspected, it is recommended that a detailed US examination be performed to rule out associated malformations. It is important to examine the pelvis in all three orthogonal planes. Therefore, tomographic US imaging was used, which allows the study of complex fetal lesions.¹⁰⁻¹² 4D visualization allows better understanding of the fetal anatomy and facilitates prenatal parental counseling.

Every pelvic cystic mass in a female fetus should include hydrometrocolpos in the differential diagnosis. Hydrometrocolpos appears as a retrovesical unilocular cystic oval- or funnel-shaped mass with low echogenicity, which is dependent on the intracystic content. It is associated with many malformations like Klippel-Feil anomaly, McKusick-Kaufman syndrome, Ellis van Creveld syndrome, and Bardet-Biedl syndrome. Ovarian cysts are rare and present as unilateral hypoechoic cystic masses. A urachal cyst appears as a unilocular cyst located between urinary bladder and umbilicus. Urinary tract obstruction appears in most cases as an anechoic megarether, urinoma, or megavesica. Anterior sacral meningocele is a very rare anechoic cystic mass extending from the sacrum to the urinary bladder. Sacrococcygeal teratoma arises in the presacral area and is the most common tumor of the newborn period. Type IV is completely internal with no external component. However, the US appearance of teratomas is very heterogeneous ranging from solid to cystic, with high vascularity.

Because the rectum and the anal canal were visualized and the kidneys were normal, complete cloacal dysgenesis as well as persistent urogenital sinus could be ruled out. Postnatal confirmation of the hydrometrocolpos caused by imperforated hymen is based on the presence of a lower abdominal mass in a female infant that does not disappear after urinary bladder catheterization.¹³ Hydrometrocolpos associated with 47,XXX karyotype and 45,XO karyotype has been described in two cases.^{14,15} In the case of sonographically detected hydrometrocolpos, karyo-

typization of the fetus is recommended, but invasive testing was refused by the patient.

REFERENCES

1. Westerhout FC Jr, Hodgman JE, Anderson GV, et al. Congenital Hydrocolpos. *Am J Obstet Gynecol* 1964;89:957.
2. Mirk P, Pintus C, Speca S. Ultrasound diagnosis of hydrocolpos: prenatal findings and postnatal follow-up. *J Clin Ultrasound* 1994;22:55.
3. Romero R, Pilu G, Jeanty P, Ghidini A, Hobbins JC. The Genital Tract. http://www.sonoworld.com/Client/Fetus/files/peda/PDCA_G.pdf.
4. Odibo AO, Turner GW, Borgida AF, et al. Late prenatal ultrasound features of hydrometrocolpos secondary to cloacal anomaly: case reports and review of the literature. *Ultrasound Obstet Gynecol* 1997;9:419.
5. Respondek-Liberska M, Krason A, Kaczmarek P, et al. Fetal hydrometrocolpos: not only diagnostic but also therapeutic dilemmas. *Ultrasound Obstet Gynecol* 1998;11:155.
6. Geipel A, Berg C, Germer U, et al. Diagnostic and therapeutic problems in a case of prenatally detected fetal hydrocolpos. *Ultrasound Obstet Gynecol* 2001;18:169.
7. Chen CP, Liu FF, Jan SW, et al. Ultrasound-guided fluid aspiration and prenatal diagnosis of duplicated hydrometrocolpos with uterus didelphys and septate vagina. *Prenat Diagn* 1996;16:572.
8. Adaletli I, Ozer H, Kurugoglu S, et al. Congenital imperforate hymen with hydrocolpos diagnosed using prenatal MRI. *AJR Am J Roentgenol* 2007;189:W23.
9. Messina M, Severi FM, Bocchi C, et al. Voluminous perinatal pelvic mass: a case of congenital hydrometrocolpos. *J Matern Fetal Neonatal Med* 2004; 15:135.
10. Kalache KD, Bamberg C, Proquitte H, et al. Three-dimensional multi-slice view: new prospects for evaluation of congenital anomalies in the fetus. *J Ultrasound Med* 2006;25:1041.
11. Devore GR, Polanko B. Tomographic ultrasound imaging of the fetal heart: a new technique for identifying normal and abnormal cardiac anatomy. *J Ultrasound Med* 2005;24:1685.
12. Goncalves LF, Espinoza J, Romero R, et al. Four-dimensional ultrasonography of the fetal heart using a novel tomographic ultrasound imaging display. *J Perinat Med* 2006;34:39.
13. Saxena R, Divan G, Long AM, et al. Fetal hydrometrocolpos. *Ultrasound Obstet Gynecol* 1993; 3:360.
14. Hood OJ, Hartwell EA, Shattuck KE, et al. Multiple congenital anomalies associated with a 47,XXX chromosome constitution. *Am J Med Genet* 1990; 36:73.
15. Koeberl DD, McGillivray B, Sybert VP. Prenatal diagnosis of 45,X/46,XX mosaicism and 45,X: implications for postnatal outcome. *Am J Hum Genet* 1995;57:661.